Title : ' ABC of CBC '

Author(s): Dr D.P.LOKWANI

Institution: NSCB Medical College, Jabalpur (M.P.) (MP Medical Science University)

Abstract:

A well executed 'CBC' followed by its proper interpretation has its worth in gold and a smart clinician can make tremendous use of this simple and cheap test for diagnosis of various disorders.

Data produced by modern hematology analyzers, offer enormous information, if properly interpreted .Unfortunately most of the clinicians and pathologists are only looking into numeric part of its output, whereas , lots of diagnostic information encrypted in the graphs (Histograms) generated by these instruments goes unused due to ignorance, as **'eyes can see only those things which brain knows'**

Hence we studied and correlated a large number of samples (from year 2002 to 2011), interpreting these graphs .

In view of variations in graphical presentations of histograms by various makes of machines, a diagrammatic representation of histograms is designed for better understanding of hematological and non hematological disorders and published in a book titled 'ABC of CBC' (by JAYPEE)

Interpretation of histograms and scatter plots, in conjunction with the numerical data can be clinically useful in the diagnosis and follow up of many hematological & non hematological conditions

- RBC, Hb, Hct, MCV, MCH all are reduced showing microcytosis with hypochromia.
- Anaemia is present.
- RDW is abnormally high due to heterogeneity of cells.
- HISTOGRAM IS ABNORMAL WITH SHIFT TO RIGHT INDICATING MICROCYTOSIS and widening of base of the graph indicating heterogeneity of cell
- The diagnosis is easily made at this point, but earlier identification would improve management.

The Diagnostic benefit of the knowledge of interpretation of HISTOGRAM and RDW is that, even at 14.4gm% Hb, forthcoming event of iron def is predicted.



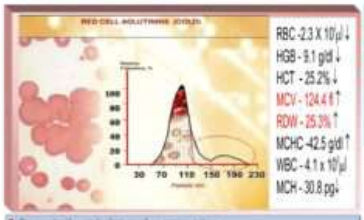

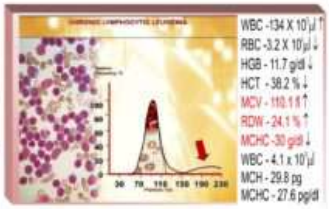

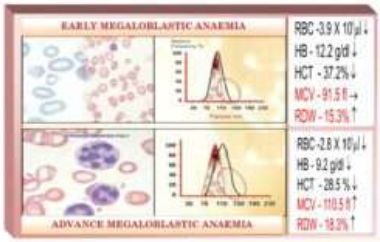

IN CASE OF ADVANCED MEGALOBLASTIC ANAEMIA WITH SEVERE FOLATE DEFICIENCY

- RBC Count is low, MCV is high, and RDW is increased.
- Histogram is widened & shifted to right distinctly, indicating macrocytosis.
- Large hypersegmented neutrophils with low Hb, increased MCV, raised RDW with presence of macro ovalocytes are considered diagnostic

IN CASE OF EARLY MEGALOBLASTIC ANAEMIA

- The MCV is still normal RBC count and Hb slightly reduced.
- RDW is distinctly increased
- Histogram is widened on right side, indicating appearance of macrocytic population, although not yet enough to increase MCV.
- Raised RDW with changes in histogram may alert the clinician for the possibility of early megaloblastic anaemia even before apparent anaemia.



EDTA INDUCED PLATELET AGGLUTINATION (EIPA)

HISTORY :
A 37 year - old male patient admitted with the C/I swelling of left lower limb.
Complete blood count (CBC) revealed.
WBC : Histogram and differentials are normal
RBC : histogram is normal
PLATELET : count is abnormally low
The platelet histogram patterns are consistent with platelet clumps, fragmented red cells, or ultra microcytic red cells.

DISCUSSION :
The situation strongly demands review of finger prick peripheral smear examination.
The finger prick smear showed numerous platelet clumps.
Numerically reduced platelets with adequate clumps on PS examination are indicative of : "pseudothrombocytopenia."
The causes usually include...

- EDTA-Induced Platelet Agglutination EIPA,
- Giant platelets,
- Fragmented red cells, or
- Ultra microcytic red cells.

On peripheral smear examination there were no giant platelets, fragmented RBC, or small RBC.

DIAGNOSIS :
PSEUDOTHROMBOCYTOPENIA

EDTA - Induced Platelet Agglutination - (EIPA)



COAGULOPATHY (DIC)

HISTORY :
A case of a 38yr old female admitted for complaints of dry cough, shortness of breath & increased bruising.

The haemogram indicated a mild anaemia & thrombocytopenia. After a haemostatic work up she was diagnosed as having DIC.

WBC - The histogram shows a smaller than normal lymphocyte curve with corresponding neutrophilia.

RBC - Histogram is unremarkable bu the RDW is increased which is consistent with the heterogeneity of the red cell morphology.

PLATELET - The histogram is consistent with thrombocytopenia and presence of mega platelets evident on the descending slope of the platelet curve and raised MPV.

Extension of the descending arm of the pit curve to the right, beyond upper discriminator, is most likely due to presence of Rad cell fragments.

DISCUSSION
Thrombocytopenia with high MPV and typical platelet histogram with ragged and extended descending arm, suggests possibility of consumption coagulopathy.
Due to peripheral consumption of platelets and Peripheral destruction, marrow was stimulated, resulting in increased production, with larger platelets.
Further investigations revealed raised D. Dimer and FDP, increased PT and APTT.

DIAGNOSIS :
CONSUMPTION COAGULOPATHY (DIC)